

FOREFOOT COMPLAINTS - THE MORTON'S METATARSALGIA. THE ROLE OF MR IMAGING

Theodossios Birbilis, Efthymia Theodoropoulou, Dimitrios Koulalis

Democritus University of Thrace, Medical School, Alexandroupolis, Greece: Department of Neurosurgery

Summary: An illustrated case with Morton's metatarsalgia is presented. MR imaging was helpful for determining the presence, location and magnitude of intermetatarsal neuroma. Moreover, it had a large influence on the differential diagnostic thinking because many disorders may produce forefoot complaints mimicking Morton's metatarsalgia.

Key words: Metatarsalgia; Morton-neuroma; MR imaging

Introduction

One of the most common causes of metatarsalgia, intermetatarsal or interdigital neuroma, consists in a degenerative alteration of one or more plantar intermetatarsal nerves and is considered a mechanical neuropathy with compression, stretching, and entrapment components in its etiology (4).

The syndrome was first described by Morton, who described "a peculiar and painful affection of the fourth metatarsophalangeal articulation" back in 1876 (3).

The diagnosis is usually made during the history and physical examination alone. In recent years, ultrasonography and neurophysiological examination are also used in the process of diagnosis. However, when the diagnosis is in doubt, a magnetic resonance (MR) imaging may be useful to confirm the neuroma and to rule out numerous other soft-tissue, bone and joint processes.

Case report

A 29-year-old woman, who used to wear high-heeled shoes, was admitted with a 6-month history of a sharp, burning pain between the left third and fourth toes. The pain was diminished after shoe removal or upon rest.

The neurological examination showed a mild hypoesthesia of the 4th toe and palpation of the third intermetatarsal space triggering acute pain. The Mulder's sign (a painful, palpable "click" between the bones) was positive, so there was the suspicion of Morton's metatarsalgia. In spite of conservative treatment (i.e., ice application, metatarsal pads, nonsteroidal anti-inflammatory drugs (NSAIDs), local anesthetic injections) the painful symptoms persisted.

Therefore, an MR imaging of the foot was performed. The T1 and T2-weighted MR Imaging showed low signal intensity of a soft-tissue mass of 1.0 cm x 1.0 cm within the third and fourth intermetatarsal space (Fig. 1a, b) as a pathognostic sign of Morton's Neuroma.

Due to persistence of discomfort, surgical treatment was recommended.

Five weeks after surgical excision of the neuroma via the dorsum of the foot, the patient was free of pain. The histological result described a peripheral nerve with perineural fibrosis, as well as epineural and endoneural hyalinisation, compatible with the diagnosis of Morton's Neuroma (2).

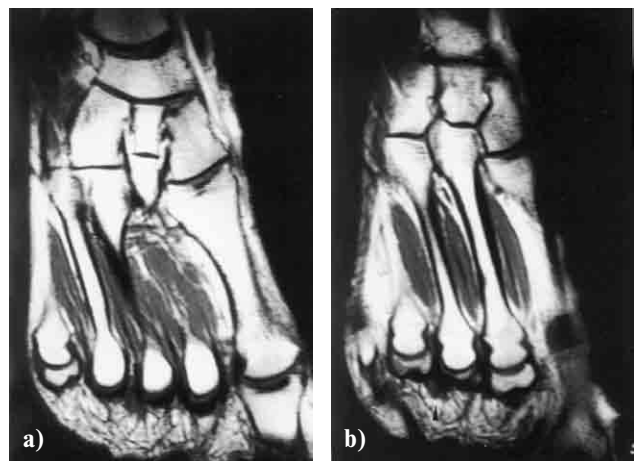


Fig. 1a, b: MRI of the foot (axial T1 - weighted image) demonstrates low signal intensity of a soft-tissue mass of 1.0 cm x 1.0 cm within the third and fourth intermetatarsal space (arrow) as a sign of Morton's Neuroma.

Discussion

Our case demonstrates that MR imaging is suitable for the evaluation of patients with forefoot complaints. Furthermore, it has a major effect on diagnostic **considerations** and therapeutic decisions when Morton's neuroma is suspected, especially because MR imaging helps in localization and size assessment of Morton's neuromas (5).

Moreover, it has a large influence on the differential diagnostic **considerations** because many disorders may produce forefoot complaints mimicking Morton's metatarsalgia (1). The most common differential diagnoses include traumatic lesions of the soft tissues and bones (e.g., stress fractures and stress reactions), infection, arthritis, Freiberg infraction, nonneoplastic soft-tissue masses (e.g., intermetatarsal bursitis), tendon disorders (e.g., tenosynovitis, ten-

don rupture), and, less frequently, soft-tissue and bone neoplasms (5)

Most processes have a combination of low signal in T1 and high signal in T2-weighted sequences, while low signal in both T1 and T2-weighted sequences is (together with the location) pathognostic for Morton's neuroma (5).

References

1. Ashman CJ, Klecker RJ, Yu JS. Forefoot pain involving the metatarsal region: differential diagnosis with MR imaging. *Radiographics* 2001;21:1425-40.
2. Graham CE, Graham DM. Morton's neuroma: a microscopic evaluation. *Foot Ankle* 1984;5:150-3.
3. Morton TG. A peculiar and painful affection of the fourth metatarsophalangeal articulation. *Am. J. med. Sci.* 1876;71:37.
4. Vachon P, Lemay M, Bouchard HL. Pathologic study of Morton's neuroma. *Can J Surg* 1991;34:356-8.
5. Zanetti M, Weishaupt D. MR imaging of the forefoot: Morton neuroma and differential diagnosis. *Semin Musculoskelet Radiol.* 2005; 9:175-86.

Submitted June 2007.

Accepted August 2007.

Corresponding author:

Theodossios Birbilis M.D., M.Sc., Department of Neurosurgery, University Hospital of Alexandroupolis, Democritus University of Thrace, Medical School, Dragana, GR-68100, Alexandroupolis, Greece, e-mail: mpirmpil@otenet.gr
